

UTERINE FIBROID EMBOLIZATION

UFE

A VIABLE ALTERNATIVE

Uterine Fibroid Embolization (UFE) is recommended by the American College of Obstetrics and Gynecology as a non-surgical alternative to hysterectomy.



>90% Women who undergo UFE have demonstrated a **HIGH LEVEL OF SATISFACTION** and a significant **IMPROVEMENT** in **QUALITY OF LIFE**, even over the long term.^{1,2}

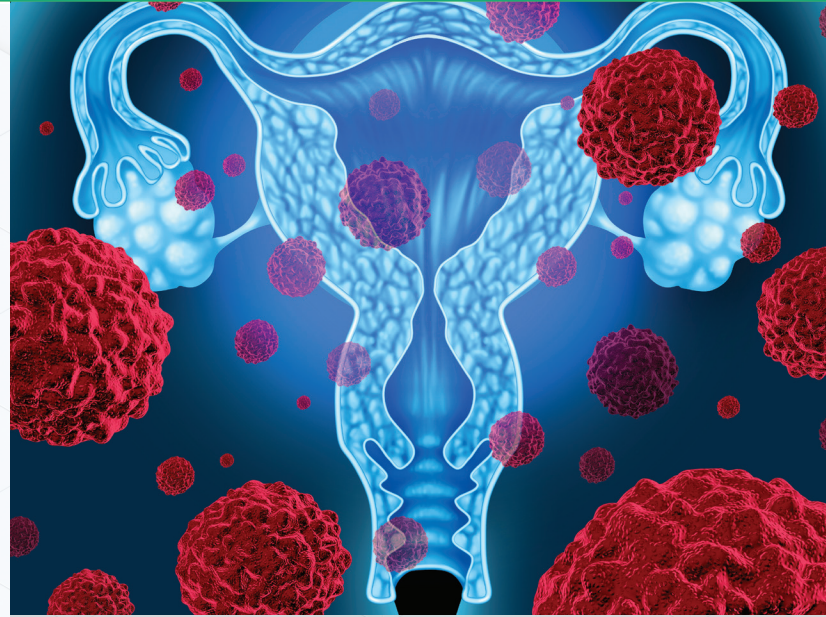
In a recent study of 4 randomized clinical trials comparing UFE to surgical interventions, UFE was associated with:



- **MINIMAL BLOOD LOSS**
- **NO HOSPITAL STAY**
- **FASTER RETURN TO NORMAL ACTIVITY.³**
- **FEWER SIDE EFFECTS**

UFE has a complication rate of 1.25%
Compared to 17-23% with hysterectomy^{5,6}

Fibroids re-occurrence after UFE is very low, compared with up to 51% of myomectomy patients who require further surgery.



THE UFE PROCEDURE

During the UFE procedure, a specially trained physician (known as an interventional radiologist) makes a small incision and inserts a catheter into the femoral artery, which extends from near the abdomen down each leg. Using imaging guidance, the catheter is guided into the blood vessels feeding the fibroid(s) in the uterus. Tiny particles called microspheres are injected into the blood vessel, which block the flow of blood into the uterine fibroid, causing it to shrink. As the fibroid shrinks, the symptoms disappear.

The physicians of North Star Vascular & Interventional have been performing UFE for many years and are among the leading experts on this procedure.

1. (8) Smith WJ, Upton E, Shuster EJ, Klein AJ, Schwartz ML. Patient satisfaction and disease specific quality of life after uterine artery embolization. *Am J Obstet Gynecol.* 2004;190(6):1697-1703.

2. Scheurig-Muenkler C, Koesters C, Poverski MJ, Grieser C, Froeling V, Kroencke TJ. Clinical long-term outcome after uterine artery embolization: sustained symptom control and improvement of quality of life. *J Vasc Interv Radiol.* 2013;24(6):765-771.

3. Laughlin SK, Schroeder JC, Baird DD. New directions in the epidemiology of uterine fibroids. *Semin Reprod Med.*

2010;28(3):204-217.

4. Spies JB, Spector A, Roth AR, Baker CM, Mauro L, Murphy-Skrynnar K. Complications after uterine artery embolization for leiomyomas. *Obstet Gynecol.* 2002;100(5 Pt 1):873-80. [PubMed]

5. Makinen J, Johansson J, Tomas C, Tomas E, Heinonen PK, Laatikainen T, et al. Morbidity of 10 110 hysterectomies by type of approach. *Hum Reprod.* 2001;16(7):1473-8. [PubMed]

6. Harkki-Siren P, Kurki T. A nationwide analysis of laparoscopic complications. *Obstet Gynecol.* 1997;89(1):108-12. [PubMed]



NORTH STAR
VASCULAR & INTERVENTIONAL

NorthStarIR.com
P: (952) 960-9399
F: (952) 206-6467

8401 Golden Valley Rd
Suite 340
Golden Valley, MN 55427

